

Dentistry Marketplace

A classic full denture case

Described by Mark Price



Figure 1: Geoff, the willing patient




Figure 2: The Kois Dento Facial Analyzer on the patient. Note the vertical facial mid-line alignment, and the moveable rubber markers that have been aligned with the eye, nose, lip and chin lines




Figure 3: The Panadent PCH articulator, showing upper cast in position, with bite rim sited on plastic index plate, and the Kois adjustable mounting platform

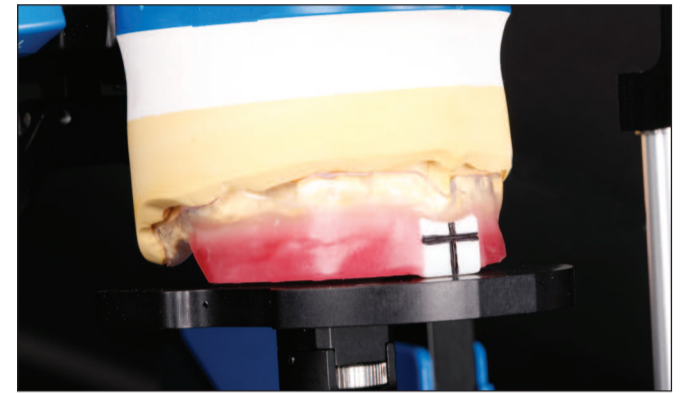


Figure 4: Upper bite rim, with 'cross hair' device in position, indicating required position of upper central incisors

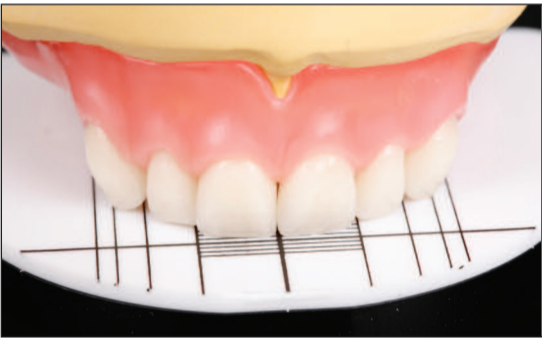

Figure 5: Upper denture positioned against waxing guide - note correct positioning of artificial anterior teeth

Figure 6: Completed upper and lower dentures on the Panadent PCH articulator

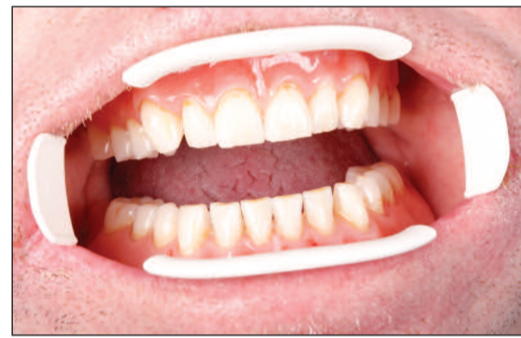

Figure 7: Geoff's completed dentures in the mouth

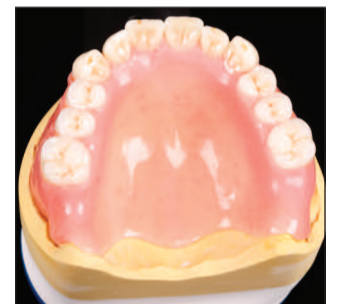

Figure 8: Palatal view of the upper denture

Setting the scene

Like most technicians, I am always ready to tackle a challenging restorative case, whether this be denture, an implant restoration or smile makeover. My objectives are always to try and help those patients who, in many cases, felt that they were a lost cause and that nobody on this earth could provide them with an effective, functional and aesthetically correct restoration.

Geoff proved to be a classic example (see Figure 1). He is 60 years old and has been without dentures for over 10 years. He had been provided with dentures in the past, but his first set proved to be a failure, so he tried again by switching to another dentist. He found that he could not keep his second set in his mouth, so resigned himself to living a life without dentures. Consequently, for the past 11 years his appearance, mouth posture and general self-esteem has suffered.

It was through Sid, my work colleague, that we got to know Geoff, and he told us his sorry tale. Like the generous, caring people we are, we decided that we could help Geoff and provide him with a fully functioning and life-like set of teeth. To this end, it was quite fortuitous that recently I came across a very simple piece of kit.

Discovering the Kois Dento Facial Analyzer

The Kois Dento Facial Analyzer is supplied by Optident. I was quite sceptical at first about its usefulness to me, being a denture orientated technician. However it proved to be of great benefit, and it was on Geoff that we decided to try it out. One of my main concerns in producing effective dentures is that it should be possible to ascertain the correct horizontal (occlusal) and vertical (sagittal) planes, and subsequently the correct alignment of the teeth.

The Kois Dento Facial Analyzer allowed this to be easily determined, and actually gets over the problem that some facebows can often present. As most facebows are really earbows, they will work well as long as there is reasonable symmetry within the cranio-facial zone. However, there are cases where the patient's ears are not in an ideal alignment and this can lead to discrepancies that will be highlighted in the appearance of the horizontal or occlusal plane.

We checked this out in Geoff's case, and estimated that, had we used a conventional earbow, the resultant horizontal plane would have been slanted by approximately 2-3mm, from upper left 3 to upper right 3. This would have led to a misleading appearance on the articulator once the models were transferred and subsequently

mounted. The Kois system proved really advantageous in this respect, as the technique does not involve the use of a conventional earbow, bitefork or transfer jig, but does allow the correct alignment of both horizontal and vertical planes. Furthermore, it also allows the distances between the eye line, the base of the nose, the high lipline and chin line to be determined (Figure 2). It is also possible at this stage to use the Golden Ruler (sometimes referred to as the Golden proportion Gauge) to measure these distances to see if they are in the correct recognised proportions of 1:1.618.

These reference lines can then be used to help ascertain more acceptable aesthetics. This can certainly be of great value when confirming the vertical dimension, as it enables the principles of Golden Proportions to be followed.

Transfer of information and set-up

The bite rim is transferred to the articulator by indexing to a white plastic index plate, using bite registration material (e.g. Kettenbach Futar D), and the upper cast is mounted using the Kois adjustable mounting platform (Figure 3).

I used the Kois Analyzer to align the upper bite rim in its correct relationship on the articulator, and as can be seen will be seen in the illustrations. I also have my own little device in the form of a pair of 'homemade' white patterns or tabs in a 'cross hair' relationship, that represents the centre line and the incisal level of the two upper central incisors. This gives me their correct position and alignment, and I place these directly onto the upper bite rim (Figure 4).

Having established the ideal width and height for these central incisors, I can use the Kois Waxing guides to help me position the anterior teeth in their correct relationship in the upper arch. I think it is most important to get the appearance of the teeth absolutely right, and the waxing guides act as a template in positioning all the upper anterior teeth. This same method also works when a diagnostic wax-up is being created in a crown and bridge case. The waxing guides use the width of the centrals as the keystone in setting all the other anterior teeth (Figure 5).

For the set-up, we used the Panadent PCH articulator, which proved to be well suited to prosthetic work (Figure 6). I particularly like the space and vertical height, and the curved incisal pin. The pin will, if the case requires, allow for accurate opening or closure of the vertical dimension. Incidentally, those dentists and technicians who

routinely use a Denar articulator can still use the Kois Analyzer as there is an adapter that allows for this.

Conclusion

As Geoff did not want his dentures to look false, we made subtle modifications to the teeth to give a more natural appearance, and set the posterior occlusion to suit his particular bite. I am now very keen to see how the Kois system will work with some of my other cases, as the instrument can be utilised, not only for dentures, but also for smile makeovers, where golden proportion principles need to be followed. However, I felt that Geoff's case provided a good initial test for the system. Its simplicity, and the way in which it provides precise information for the dental team, can only aid in achieving an ideal result.

As for Geoff, there has been a significant change, not only in his appearance, but also in the way he can function with the dentures. The change in his muscle function is incredible, and his jaw has ceased 'wandering' forward. The jaw movements also now appear natural and with vertical dimension restored, he has much improved aesthetics (Figure 7). The completed upper denture is shown from the palatal aspect (Figure 8). All in all, I am very satisfied with the result - and so is Geoff!

The products described here are available from Optident Ltd. I.D.C., Valley Drive, Ilkley, West Yorkshire, LS29 8AL. Full details and a free Kois Dento Facial Analyzer instructional mini disc is available on request. Tel 01943 605050 or email sales@optident.co.uk.

Mark Price specialises in prosthetics and operates from Elite Dental Studios in Ripon, North Yorkshire. He works in conjunction with a consulting dentist to provide a personalised, two-day, high-quality denture service. Mark gives credit for his acquired skills to his former employer and mentor, Tony Kitchen. He also offers a course for dental practitioners wishing to extend their knowledge in specialised dental prosthetics. Mark can be contacted at Elite Dental Studios, 22, High Skellgate, Ripon, North Yorkshire, HG4 1 BD. Tel. 01765 608001. Email: markprice@elitedentalstudios.co.uk or visit www.elitedentalstudios.co.uk.

